

Case report of the efficacy of magnetic attachments with upper complete denture using implants for different skeletal types.

Wataru Atsuta^{1,2}, Yuka Atsuta¹, Maya Iwamoto², Jin Ashizawa², Takeshi Kanno², Kazumasa Hoshino², Toshiyuki Mizuguchi², Jyoji Tanaka²

¹Blossom Dental Office, Tokyo, Japan

²Clinical Implant Society of Japan

Abstract: The aim of this presentation is to consider the utility of implants and magnetic attachments in the case of complete overdentures with different skeletal types. Those upper complete overdentures in the maxilla of two patients diagnosed class II and class III skeletal types were not enough getting stability due to unique problems of remaining teeth position and skeletal types.

Case 1 First visit: October 2012, 62-year-old female.

This patient exhibited skeletal class II type. The upper prosthesis transitioned from a fixed bridge to a complete denture. Dental implants were placed in 6[┐]6, and a magnetic attachment was attached.

Case 2: First visit: January 2013, A 58-year-old male.

This patient exhibited skeletal class III type. The upper prosthesis was transitioned from using clasps denture to a maxillary complete denture with the remaining 2[┐]235 teeth and placed 76[┐] dental implants and attached the magnetic attachments.

Those problems were solved by using dental implants and magnetic attachments for modified fulcrum lines of the residual roots and retentive force. It has been suggested that the use of dental implants and magnetic attachments were very useful in cases with such complex problems.

I. Introduction

There are some factors that inhibit of stability of maxillary complete dentures. Skeletal type is one of them. Complete overdentures case in the maxilla of two patients diagnosed class II and class III skeletal types were not enough getting stability due to unique problems of remaining teeth position and skeletal types. In such cases, it was difficult to solve the problem with complete denture treatment techniques only. We reported experienced that the problem could be solved by using dental implants and magnetic attachments.

II. Objective

The aim of this presentation is to consider the utility of implants and magnetic attachments in the case of complete overdentures with different skeletal types.

III. Materials and Methods

1 Patients' data Case1

Case 1 First visit: October 2012, 62-year-old female.

This patient exhibited skeletal class II type. The upper prosthesis was transitioned from a fixed bridge to a complete denture due to removing teeth for periodontitis. Dental implants were placed in 6[┐]6, and a magnetic attachment was attached (Fig.1~3).

Fig.1 Pre-treatment intra-oral view

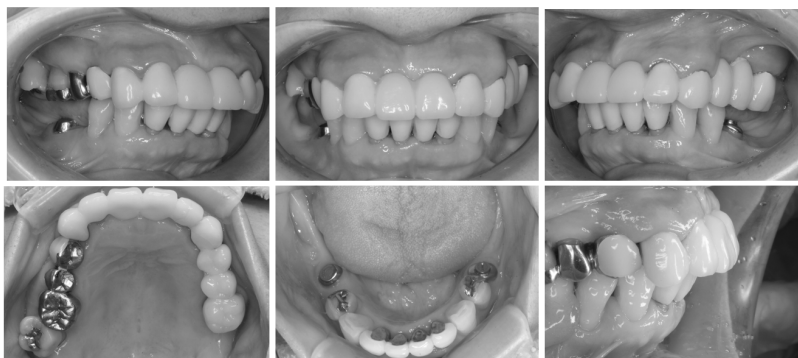


Fig.2 Comparison of pre and post initial periodontal therapy for Panoramic X-ray.

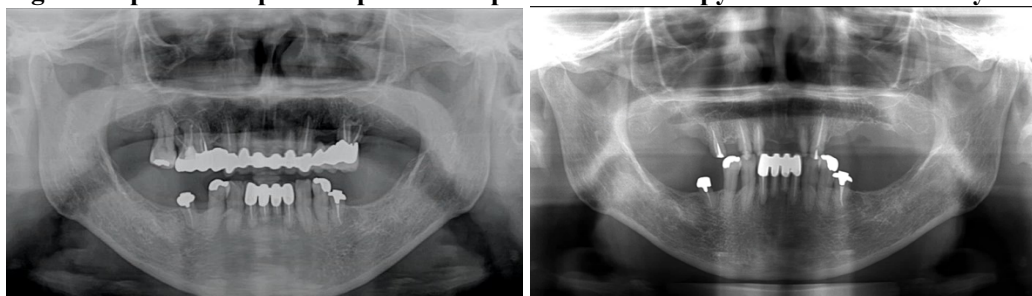


Fig3 Analysis of ANB for CBCT and problem list

ANB : 6.25° (Japanese female 3.05 S.D. 1.23)

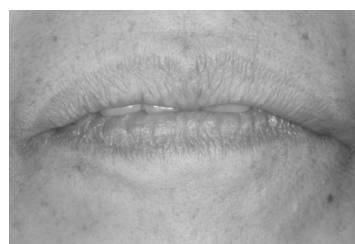Diagnosis: Skeletal maxillary protrusion

Skeletal Class II

Periodontitis classification Stage IV Grade B

Problem list: Lip incompetence

Weak gagging reflex



2 Patients' data Case2

Case 2: First visit: January 2013, A 58-year-old male.

This patient exhibited skeletal class III type. The upper prosthesis was transitioned from using clasps denture to a maxillary complete denture with the remaining 2^L235 teeth and placed 76^L dental implants and attached the magnetic attachments.

Fig.3 Pre-treatment intra-oral view

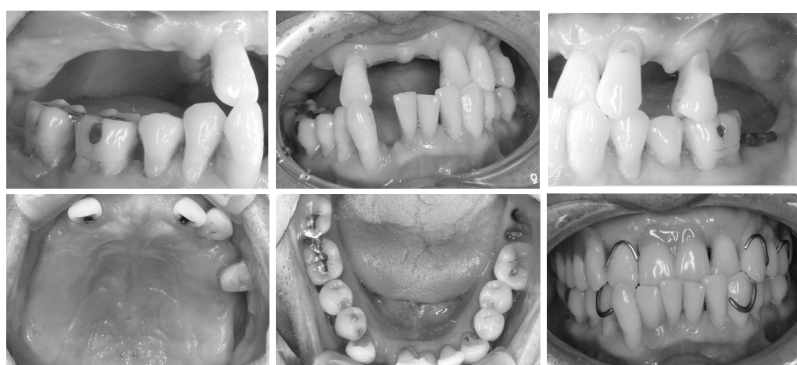


Fig.4 Comparison of pre and post initial periodontal therapy for Panoramic X-ray.

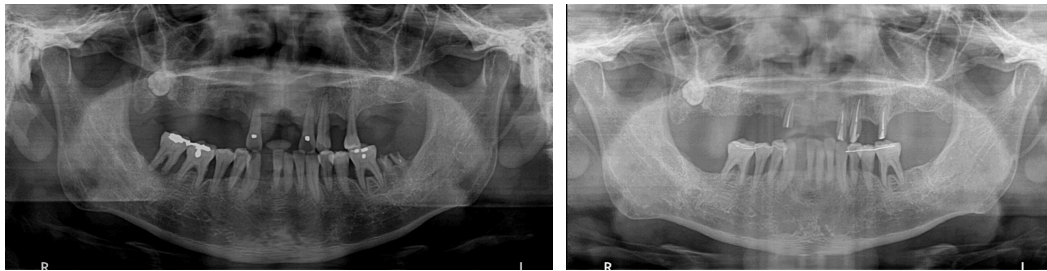


Fig.5 Analysis of ANB for CBCT and problem list

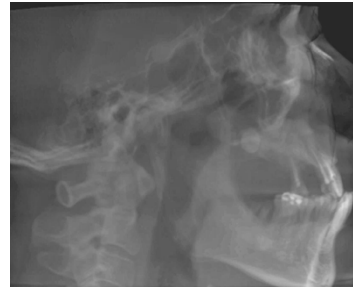ANB : -0.57° (Japanese male 2.34 S.D. 1.30)

Diagnosis: Skeletal reversed occlusion

Skeletal Class III

Periodontitis classification Stage IV Grade C

Problem list: Occlusal form in which the denture
is pushed up by the lower anterior teeth.
Desiring a short posterior denture border.

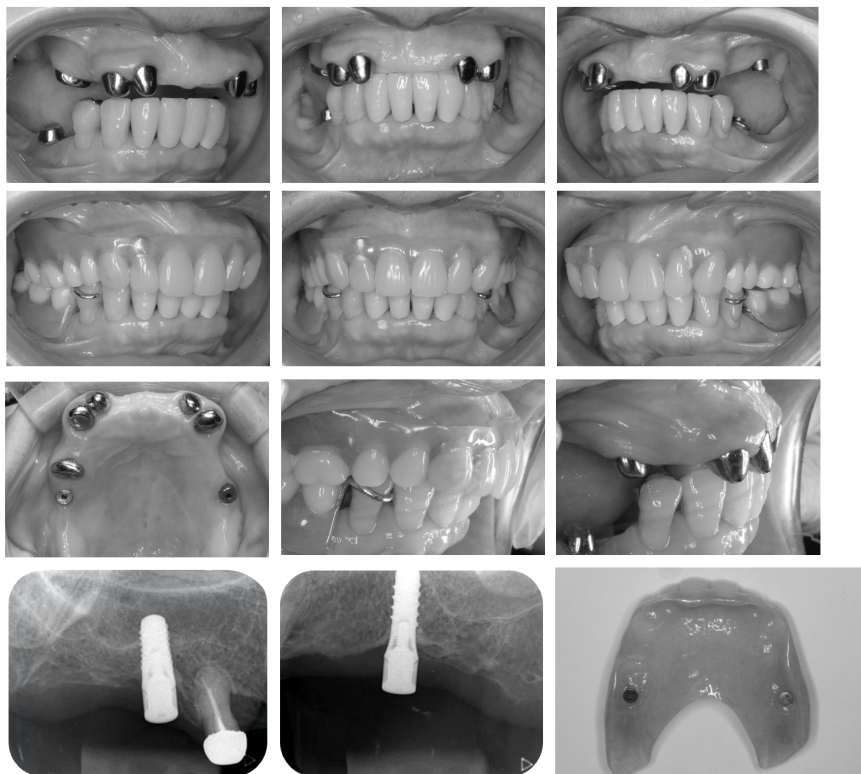


IV. Results

1 Case1: 6⁻6 dental implants placement and magnetic attachments for Skeletal Class II

By preserving the maxillary anterior teeth, the alveolar ridge was maintained, resulting in a further tendency for maxillary protrusion. In order to improve the lip incompetence, it was necessary to shorten (thin) the labial denture flange and further shorten the short posterior denture border, so dental implants were placed at 6⁻6 and magnetic attachments were attached to maintain the denture. As a result, the lip incompetence was improved, and the dentures were able to suction well (Fig.6).

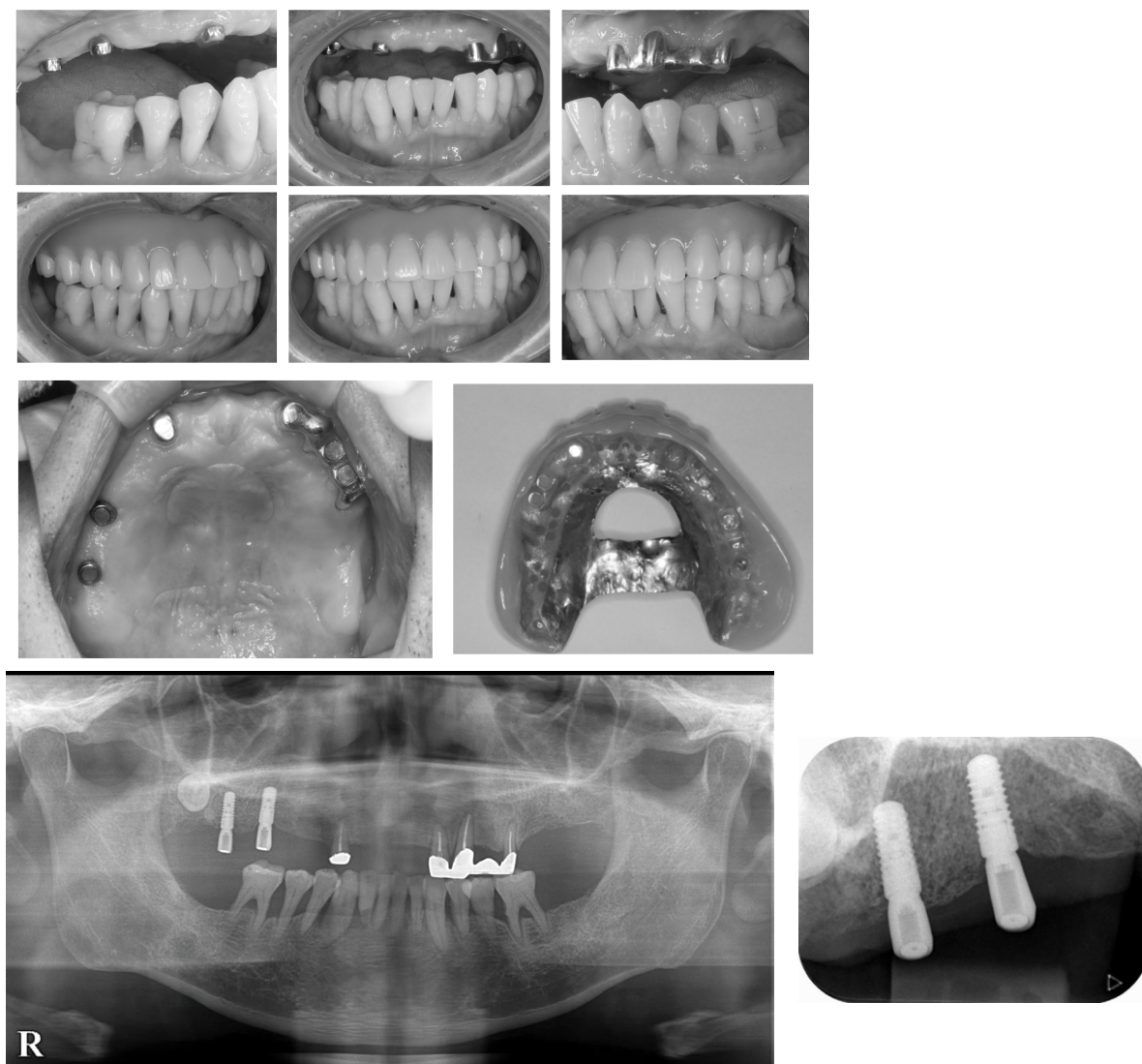
Fig.6 Post-treatment intra-oral view (After 3years of wearing denture) and X-ray



2 Case2: 76^{-L} dental implants placement and magnetic attachments for Skeletal Class II

When improving the anterior occlusal relationship in a reversed occlusion, pushing up of the mandibular anterior teeth can cause the denture to fall out, so to preserve the remaining teeth in the anterior region. And it was placed dental implants at 76^{-L} sites because of further increasing the denture support area. Furthermore, a magnetic attachment was added to provide suction. The patient wanted the posterior denture border to be shortened, and this was achieved by magnetic attachment's function (Fig.7).

Fig.7 Post-treatment intra-oral view (After 1.6 years of wearing denture) and X-ray (After 7 years)



V. Discussions

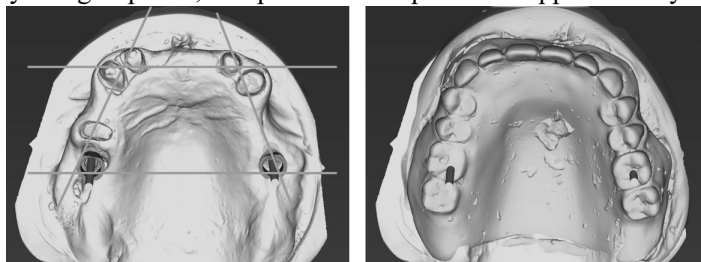
Maxillary complete dentures are generally maintained by suction, but denture stability may not be achieved due to various inhibiting factors, and skeletal class II and III are considered to be one of the inhibiting factors. In case of skeletal class II, in addition to the over angle of convexity of the labial side, the denture flange suffers from insufficiency of entrance lip closure, resulting in constant lip pressure, and the undercut becomes strong, resulting in a shortening of denture flange. Furthermore, in class III, the denture falls out due to pushing up of the mandibular anterior teeth. To solve these problems, if there is a residual root, the stability of the denture can be improved by widening the support area surrounded by the fulcrum line and aiming for bilateral symmetry, but it is difficult to maintain the denture due to poor suction. In such cases, the use of implants and magnetic attachments has made it possible to increase the support area of the denture and obtain suction. It was also suggested that the use of magnetic attachments could satisfy the gag reflex

and the desire of a certain number of patients to shorten the trailing edge of their dentures (Fig.8).

Fig.8 Simulation of dental implant placement position and denture support area

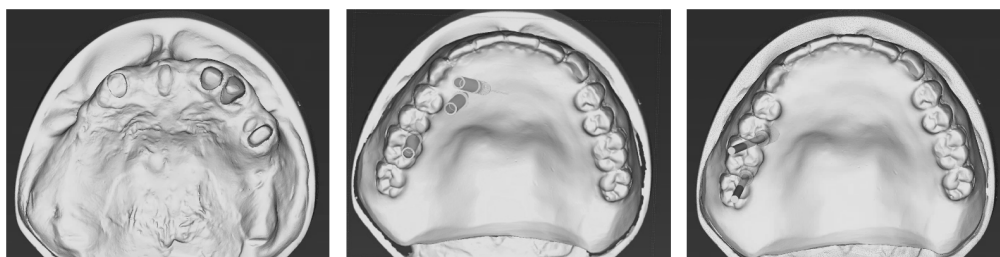
8-1 Case1: 6- $\bar{1}$ -6 dental implants placement

By using implants, it is possible to expand the support area symmetrically.



8-2 Case2: 76- $\bar{1}$ dental implants placement

This case was diagnosed as having severe reverse occlusion, and it was diagnosed that it would be difficult to place it on the anterior teeth. The implant was placed in a position where it could be placed on the alveolar crest of the denture, with the aim of widening the support area.



VI. Conclusions

Those problems were solved by using dental implants and magnetic attachments for modified fulcrum lines of the residual roots and retentive force. It has been suggested that the use of dental implants and magnetic attachments were very useful in cases with such complex problems.

References

- 1) Jyoji T, Fundamentals and clinical applications of implant overdentures,12-29, Ishiyaku Publishers,Inc. Tokyo, 2020.